

Eye Problems and Ectodermal Dysplasia

by Mr Colin E Willoughby, FRCOphth
Lecturer in Ophthalmology

Introduction

An ectodermal dysplasia (ED) is disorder that results from abnormal formation of the ectodermal layer in the developing embryo. The ectoderm of the embryo forms the hair, teeth, nails, sweat glands and parts of the eyes. The ectodermal dysplasias are a diverse group of conditions and over a 100 different types have been described.

To understand the eye problems in ED, you must understand the basic structure and function of the eye. This page will briefly describe the anatomy of the eye and how the eye develops in the embryo, in particular the role of the ectoderm. How different structures and functions of the eye are affected by ED will be covered, leading into the treatments available for different ocular problems, and to finish, a look to the future.

Basic Eye Structure

The eye consists not only of the globe but also the surrounding structures - the lids, the tear drainage passage and the tear or lacrimal gland. The globe of the eye consists of an outer coat, a middle layer and an inner layer. The outer coat is made up of a tough fibrous, white layer - the sclera, and a clear transparent window - the cornea. The middle layer contains pigment and forms the iris. The inner layer is the light seeing layer or retina. The lens is an oval disc which sits behind the pupil and iris.

The cornea focuses 2/3 rds of the light entering the eye and the lens 1/3 rd.

The cornea must be healthy for the eye to function. The cornea depends on the lids, the conjunctiva (the transparent membrane inside the lids covering the white of the eye), and tear or lacrimal gland, and tear film to maintain its function, keeping the eye healthy and comfortable.

Tears form a film over the surface of the eye - cornea/conjunctiva/sclera. The tear film has three layers forming a sandwich over the eye. The outer layer is made up of an oil layer. The oil is produced by glands found in the lids called meibomian glands. The inner layer is a mucus layer which is made by the conjunctiva. Sandwiched between these layers is a thick filling of water from the tear or lacrimal gland. This water layer contains chemicals and substances which nourish the eye surface. The tears eventually evaporate or drain into the nose through a drainage system called the nasolacrimal duct.

Eye Development

The formation of the eye is a complex process which starts as early as the fourth week of gestation. The eye forms from three main tissues - the brain/nervous system tissue (neuro-ectoderm), a middle layer (mesoderm) and an outer layer (the ectoderm). The ectoderm forms the outer parts of the embryo - skin, hair, sweat glands, teeth and parts of the eye and ear.

A cystic outgrowth from the brain will form the eye. The surface layer (skin) overlying this cystic area is the ectoderm. The lens buds off this outer ectodermal layer to lie inside the developing eye. The ectoderm closes the gap forming the outer part of the cornea, conjunctiva, lids, lacrimal gland and nasolacrimal duct.

Eye Involvement in ED

Eye problems are known to occur in ED but how common and the specific ways the eyes are involved is not fully understood. Eye problems do seem to differ between the different types of ED and can vary in severity. As already discussed, structures of the eye formed from the ectoderm are affected by ED. The function and comfort of the eye is therefore disturbed. The ocular involvement can be divided into 4 main areas:

1) Tears

The health of the surface of the eye - conjunctiva and cornea depends on the tears. The tears bathe the ocular surface with nutrients and moisture like the water and fertiliser in a garden. The lacrimal gland produces the 'water' component of the tears which contain growth factors and substances to ensure ocular health and comfort. The function of this gland can be affected by ED. The oil layer which floats on the 'water' layer seals the tears against the eye and is secreted from the meibomian glands in the eyelids. These glands can be absent in ED - failing to form in the embryo. Abnormalities in this oil layer allow the tears to evaporate increasing tear deficiency. The 'water' layer sits on a thin layer of mucus produced from the conjunctiva which allows the tears to flow and wet the eye surface.

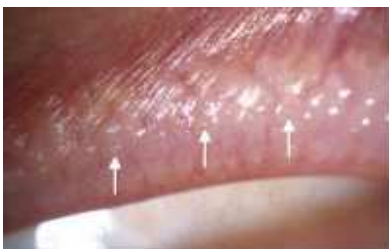

Image 1 Normal lid margin indicating meibomian gland orifices (arrows).

[View larger version of Image 1](#)

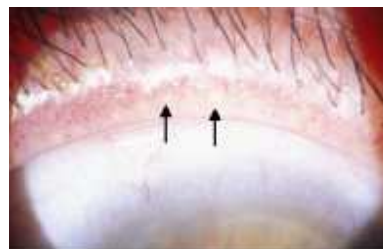


Image 2 Lid margin of a female carrier of anhidrotic ectodermal dysplasia (EDA) demonstrating

meibomian glands (arrows) reduced in number and with abnormal secretions.

[View larger version of Image 2](#)

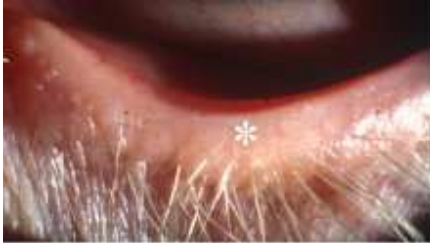

Image 3 Absent meibomian glands (asterix) in a patient with ectrodactyly-ectodermal dysplasia-cleft lip/palate (EEC) syndrome.

[View larger version of Image 3](#)

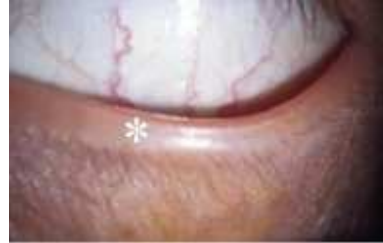

Image 4 Affected son with EDA of the female carrier shown in Image 2. There are no meibomian glands in lid margin (asterix).

[View larger version of Image 4](#)

The oil, water and mucus layer can therefore, all be affected by ED. Defects in the tear film causes changes in the conjunctiva and cornea resulting in a diseased 'ocular surface'. This can predispose to infection, lead to corneal ulceration and delay healing.

2) Cornea

The outer surface of the cornea, the corneal epithelium, forms from the ectoderm and requires the tears to function normally. The cornea is the window of the eye focusing and allowing light to enter the eye - its function is essential for vision. The surface of the cornea is renewed every 7-14 days. Tissue at the edge of the cornea continually forms the corneal epithelium from stem cells. From my experience in ED these stem cells are affected in some types of ED. This leads to an unhealthy cornea which can result in defects in the corneal epithelium, ulcers and scarring.

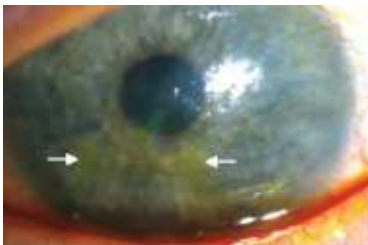

Image 5 Corneal epithelial defect (arrows) stained with fluorescein 2% in a patient with EEC syndrome.

[View larger version of Image 5](#)

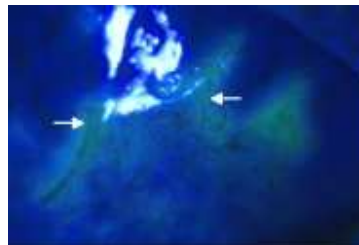


Image 6 Cornea in Image 5 viewed with cobalt blue filter producing fluorescence of epithelial defect, enhancing visualisation.

[View larger version of Image 6](#)

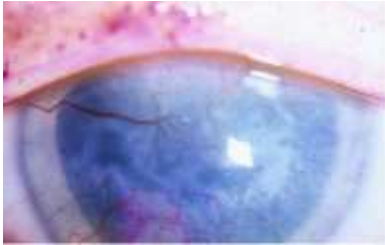


Image 7 Opaque cornea with radial new vessels and ocular surface disease in a patient with EEC syndrome.

[View larger version of Image 7](#)

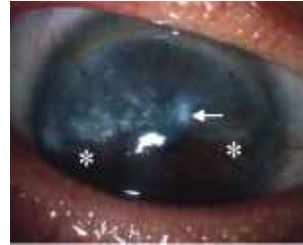

Image 8 Superior corneal pannus (scarring and vascularisation) (area above asterisks) with Salzmann's nodular degeneration (arrow) in a patient with EEC syndrome.

[View larger version of Image 8](#)

3) Lens

The lens forms from the surface skin or ectoderm and can have opacities within it in ED. Opacity of the lens results in defects in focus and clarity of vision and is termed a cataract.

4) Tear Drainage

The tear drainage system drains tears from the eye into the nose. Obstruction in this system can occur leading to watery eyes especially from birth and increases the risk of infection within this drainage system. Infection of the tear drainage sac is called dacryocystitis.

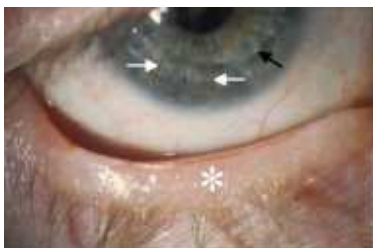

Image 9 Corneal graft (penetrating keratoplasty) in a patient with EEC syndrome. Edge of disc shaped transplanted cornea can be seen (black arrow) and nylon sutures (white arrows).

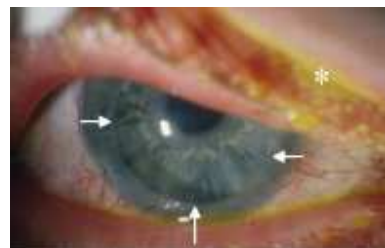

Image 10 Corneal graft in patient with EEC syndrome. Edge of clear transplanted cornea can be seen (white arrows) with opaque peripheral rim of remaining host cornea. Original cornea (black arrow).

(white arrows).

[View larger version of Image 9](#)

would resemble that in Image 7. Asterisk shows residual 2 % fluorescein eye drop used to assess corneal graft for epithelial defects and ulcers.

[View larger version of Image 10](#)

Treatment

The underlying causes of eye disease in ED are not fully understood, and so treatment is aimed at symptomatic relief rather than cure or prevention. Tear supplements increase comfort but natural tears contain many substances other than just 'water' so the surface of the eye can still remain unhealthy. Antibiotics and topical steroids are used to control infection and reduce inflammation. Photophobia can result from a diseased ocular surface and in my experience seems particularly severe and common in ectrodactyly-ectodermal dysplasia-cleft lip/palate (EEC) syndrome. Corneal ulcers are treated by a variety of measures - antibiotics, tear supplements, patching and special contact lens termed bandage contact lenses.

Surgery may be required for blockage of the nasolacrimal duct and this includes syringing and probing the system (usually done in childhood) and a operation to 're-plumb' the duct into the nose - a dacryocystorhinostomy or DCR for short!

Cataract surgery can be performed if cataracts are reducing the vision. Rarely corneal transplants have been performed to replace a scarred cornea with healthy tissue. The outcomes from corneal transplantation is uncertain due to the other changes in the ocular surface - like planting a seed in dry, barren soil. Recent advances in reconstructing the ocular surface and corneal transplantation may be more successful in the future.

Future/Research

As knowledge increases about the underlying genetic causes of the many types of ED, this can be used to study the eye problems in ED.

At the moment I can only really inform you of the research that I have been developing in ED and eye problems. I established the Ectodermal Dysplasia Ophthalmic Research Group in Liverpool in 1997 after seeing patients mainly with EEC syndrome in the eye department. The group consists of Mr Stephen Kaye (Consultant Ophthalmologist specialising in corneal surgery and paediatric ophthalmology and his colleague Mr Mark Batterbury (Consultant Ophthalmologist) also specialising in corneal disease; Professor Ian Grierson (Professor of Experimental Ophthalmology); Dr Paul Hiscott (Clinical Senior Lecturer in Ophthalmic Pathology) and myself.

Our first goal, is to investigate the nature and prevalence of ocular disease in the ectodermal dysplasia (ED). A national study to describe and document the ocular features

in ectodermal dysplasia is underway. Some of our patients have undergone corneal transplantation and by studying ocular tissue from patients we aim to understand the pathogenesis of eye disease and corneal scarring in ED. In particular, EEC syndrome in which corneal scarring is more common is under active study.

In the Experimental Ophthalmology Unit, University of Liverpool, basic science research has been commenced to investigate the genetic and molecular basis of the eye problems in ED. The role of specific genes and peptide growth factors in ED are being investigated. We are also analysing the development of the eye in ED, which ocular structures are affected by ED and the pathogenesis of ocular disease in ED. Only by increasing our understanding of these areas, can we then hope to improve treatment.

This article was published on this website in November 2000